The Neurodiagnostic Journal

ISSN: 2164-6821 (Print) 2375-8627 (Online) Journal homepage: http://www.tandfonline.com/loi/utnj20

Extreme Spindles and Leukoencephalopathy after Acute Lymphoblastic Leukemia Treatment: An Undescribed Association

Paulo Afonso Medeiros Kanda Ph.D., Rafael Guimarães Kanda, Paulo Afonso Mei M.D. & Ivan José Cury M.D.

To cite this article: Paulo Afonso Medeiros Kanda Ph.D., Rafael Guimarães Kanda, Paulo Afonso Mei M.D. & Ivan José Cury M.D. (2015) Extreme Spindles and Leukoencephalopathy after Acute Lymphoblastic Leukemia Treatment: An Undescribed Association, The Neurodiagnostic Journal, 55:4, 235-242, DOI: 10.1080/21646821.2015.1092779

To link to this article: http://dx.doi.org/10.1080/21646821.2015.1092779

Published online: 04 Nov 2015.

The Neurodiagnostic Journal, 55: 235–242, 2015

ISSN: 2164-6821 print / 2375-8627 online
DOI: 10.1080/21646821.2015.1092779

Extreme Spindles and Leukoencephalopathy after Acute Lymphoblastic Leukemia Treatment: An Undescribed Association

Paulo Afonso Medeiros Kanda, Ph.D.[1]; Rafael Guimarães Kanda[2]; Paulo Afonso Mei, M.D.[3]; Ivan José Cury, M.D.[4]

[1]*Neurovale Laboratory of Neurophysiology and EEG*
Taubate, São Paulo, Brazil
[2]*Faculty of Medicine of Botucatu*
State University of São Paulo (UNESP)
São Paulo, Brazil
[3]*Department of Neurology*
University of Campinas (Unicamp)
São Paulo, Brazil
[4]*Department of Neurology and Neurosurgery*
Hospital Vicentino
Ponta Grossa, Parana, Brazil

ABSTRACT. *We report a case of a child whose EEG demonstrated extreme spindles (ES) after acute lymphoblastic leukemia treatment. This finding has not been reported previously. In 1962, Gibbs and Gibbs described the ES EEG pattern due to its high amplitude (200 to 400 μV). ES are a rare spindle variant that is found in EEGs of 0.05% of normal children (average age, 3 years, with a range of 1 to 12 years), and are even rarer after 11 years. Moreover, due to changes in the white matter of the frontal lobe, ES have been associated with such conditions as cerebral palsy and mental retardation, residual brain damage, undefined infections, infantile neuroaxonal dystrophy, Menkes' kinky-hair syndrome, congenital muscular dystrophy, hydrocephalus, porencephaly, epilepsy, progressive cerebellar degeneration, and mycoplasma encephalitis. Methotrexate has a notably toxic effect on the central nervous system, with leukoencephalopathy being the most common form. In our case, frontocentral ES were associated with hyperintense lesions in the white matter of the frontal lobe. Lesional deafferentation can be the substrate*

Corresponding Author's E-mail: pkanda@sinapsy.com.br
Received: June 10, 2015. Accepted for publication: September 8, 2015.
Color versions of one or more of the figures in the article can be found online at www.tandfonline.com/utnj.

for an almost continuous ES, since both initiation and termination of spindle oscillations are thought to originate in thalamocortical neurons. Thus, we postulate that in some cases a partial functional cortical differentiation could generate ES.

KEY WORDS. *EEG, EEG variant, extreme spindles, leukoencephalopathy, lymphoblastic leukemia.*

We present here a previously undescribed association of methotrexate (MTX) in acute lymphoblastic leukemia (ALL) and extreme spindles (ES) on EEG. Sleep spindles constitute an EEG hallmark of sleep synchronization in stage 2 non-REM sleep, are rhythmic and monomorphic waves (10–14 Hz), with a maximum amplitude in the vertex (Cz), radiating to the central, temporal, and parietal regions (Spinosa and Garzon 2007). Gibbs and Gibbs described the ES EEG pattern in 1962. This rare pattern is an abnormal spindle variant that is found in EEGs of 0.05% of normal children (average age, 3 years, with a range of 1 to 12 years), and are even rarer after 11 years. They are diffuse and are seen even in the waking state, though when the patient is awake they are of low to medium voltage and are mixed with waking activity (Gibbs and Gibbs 1962). Moreover, due to changes in the white matter of the frontal lobe, ES have been associated with such conditions as cerebral palsy and mental retardation (Shibagaki 1980), residual brain damage, undefined infections, infantile neuroaxonal dystrophy, Menkes' kinky-hair syndrome, congenital muscular dystrophy, hydrocephalus, porencephaly, epilepsy, progressive cerebellar degeneration, and mycoplasma encephalitis (Heatwole 2005).

CASE REPORT

A previously healthy three-year-old boy developed a low-grade persistent fever for three months, with throat pain and weight loss. A bone marrow biopsy revealed precursor B-cell acute lymphoblastic leukemia (ALL) with 70% blasts (in normal bone marrow, the blast count is 5% or less). Lumbar puncture was performed before systemic chemotherapy and did not show central nervous system (CNS) involvement. The patient was diagnosed with B-cell type ALL and treated according to the recommendations of The Brazilian Cooperative Group for Treatment of Childhood Acute Lymphocytic Leukemia (GBTLI) (Brandalise 1994) with dexamethasone, vincristine, daunorubicin, cytarabine, l-asparaginase, MTX, and 6-Mercaptopurine. Furthermore, the patient received intrathecal prophylaxis with dexamethasone, cytarabine, and dexamethasone. Seven months after completing ALL treatment, he then presented with weakness, fatigue, and lethargy. Laboratory investigation revealed bone marrow biopsy with less than 5% blasts, normal immunophenotyping, and normal cerebrospinal fluid examination. T2-weighted magnetic resonance imaging revealed hyperintense lesions in the white matter of the frontal lobe, suggestive of leukoencephalopathy

(LE), and an EEG showed diffuse slowing. The patient improved within 10 days without any treatment.

Forty-two months following diagnosis, the patient began to experience focal seizures with impairment of awareness and bilateral convulsive seizures. A seizure medication regimen of sodium valproate 1000 mg/day and clobazam 10 mg/day was prescribed. While on this medication regimen, the patient experienced a generalized seizure, which was treated with intravenous diazepam, and an EEG recording was obtained five days following the seizure. The EEG showed 14-16 Hz ES characterized by continuous and high-amplitude (maximum voltage 147 μVolts), bilateral frontal spindles with a very diffuse spreading and sharp morphology (Figure 1). Twenty days later, a new EEG showed the same diffuse spindle pattern with higher amplitude (maximum voltage 300 μV) (Figure 2). After the second EEG record, phenobarbital (100 mg/day) was added to the treatment. A follow-up EEG five months later showed that ES had disappeared and background activity was normal (8 Hz in posterior leads). He was still taking the prescribed medication regimen of sodium valproate, clobazam, and phenobarbital at the same doses described previously. Nonetheless, this EEG showed brief (less than 3 s) and fragmented interictal generalized spike-slow waves (3–4 Hz), with frontal predominance of amplitude (Figure 3). We did not find a focus in any of the three EEG records.

DISCUSSION

MTX has a notably toxic effect on the CNS, with LE being the most common form (Reddick 2005). There are many other CNS toxic effects associated with MTX: hemiparesis, quadriparesis, seizures, transient paresis, or cerebellar abnormalities. The mechanism of MTX-induced neurotoxicity is poorly understood. Both high-dose intravenous MTX and intrathecal MTX are proposed to have association with demyelination, white matter necrosis, loss of oligodendroglia, axonal swelling, microcystic encephalomalacia, and atrophy relatively selective for the deep cerebral white matter (Cyriac 2008). Higher doses and more intravenous courses of MTX place patients at a higher risk for LE, although many of the adverse effects resolve after the completion of therapy. Once again, the prevalence of LE varies according to the time when the evaluations are performed, with a prevalence of 0% at baseline and at the beginning of consolidation, 18–76% (median, 38%) during therapy, and 5–53% (median, 20%) after therapy (Reddick 2005). The effect of these changes on neurocognitive functioning and quality of life in survivors remains to be determined.

To our knowledge, this is the first report of ES and LE after ALL treatment. Extreme spindles were named in reference to their high amplitude (200–400 μV) and represent an unusual variant of sleep spindles activity (Spinosa and Garzon 2007) with a wide frequency range (6–8 Hz) (Niedermeyer 2011). They have maximum amplitude in frontocentral regions and occur virtually continuously throughout the recording

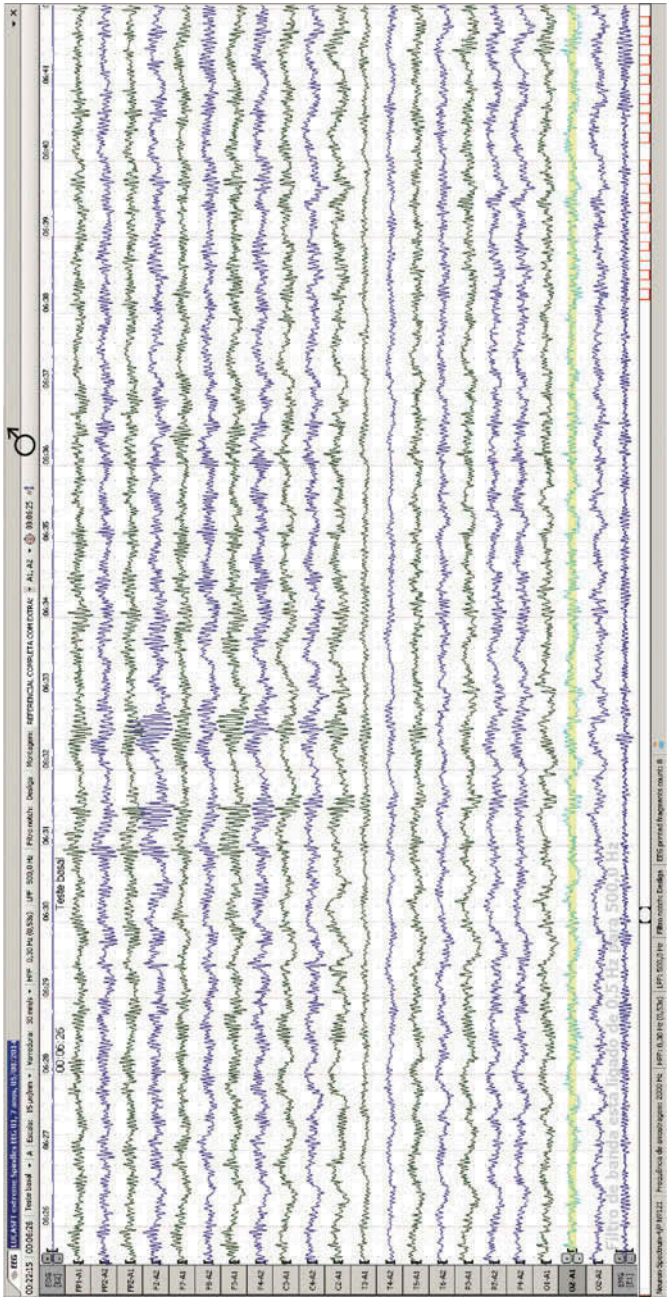

FIG. 1. Extreme spindles appear as an exaggeration of normal sleep spindles. The pattern is continuous with a frequency of 8 to 15 Hz and is of much higher voltage than sleep spindles.



FIG. 2. A new EEG recorded 20 days later showed the same diffuse spindle pattern with higher amplitude (maximum voltage 300 μV).



FIG. 3. Follow-up EEG, five months later, showed that ES disappeared and background activity was normal (8 Hz in posterior leads) with brief (less than 3 s) and fragmented interictal generalized spike-slow waves (3–4 Hz) with frontal predominance of amplitude.

(Westmoreland and Klass 1990). They differ from typical sleep spindles, which have lower amplitude (less than 50 μV), duration of 1 to 4 seconds, and show maximum amplitude in the vertex (Cz), with bilateral diffusion to central regions (C3 and C4) (Spinosa and Garzon 2007). It is also important to differentiate ES from other rapid activity observed in patients using drugs that enhance rapid activity, such as benzodiazepines or barbiturates. Rhythmic fast activity increases with therapeutic doses of both benzodiazepines and barbiturates. Barbiturates induce discrete runs of frontal beta activity at a frequency of 18–24 Hz. With benzodiazepines, rhythmic beta activity increases during drowsiness and it is more pronounced after acute administration (Ebersole and Pedley 2003). Unfortunately, differentiation between ES and these rapid activities can be challenging. We used some clues to the diagnosis of ES: the very high amplitude (in our case 300 μV), the diffuse spread with frontocentral predominance, the continuous and sharp morphology, and the complete disappearance of the pattern after 5 months without any medication change. Furthermore, beta rhythms from diazepines and barbiturates have lower amplitude than ES. Transient ES are rare. They have previously been reported in one case of subacute Mycoplasma pneumoniae encephalitis (Akaboshi 1998) . Currently, while his leukemia is in remission, this seven-year-old boy has epilepsy, with seizures that are difficult to control.

The hypothesis of thalamic reticular nucleus (RE) as the generator of sleep spindles originates from the observation that RE produces focal spindles even if disconnected from thalamic-cortical neurons and that thalamic nuclei spindles were abolished by disconnection from RE (Steriade 1985). Spindles can present some topographic variations. They project with a maximum at the vertex (14 Hz) in light sleep, progress to involve more generalized areas of both cerebral hemispheres (10 Hz) in a moderately deeper sleep, and present frontal maximum (12 Hz) in a more profound light sleep. Niedermeyer and Capute (1967) originally described ES as an abnormal spindles variant, which they observed in four children (ranging from 3 to 13 years old) with organic brain disease. ES occurring in childhood and adolescence may be asynchronous and have variable distributions with a common accentuation in central and frontal areas. In our case, ES were found after ALL remission. Consequently, neoplastic involvement was not the cause of the appearance of ES. In addition, the frontocentral ES were associated with hyperintense lesions in the white matter of the frontal lobe. During sleep spindles, the medial prefrontal cortex is functionally "deafferented" from its hippocampal inputs, based on processes of cortical origin, and presumably mediated by the strong recruitment of inhibitory interneurons (Peyrache 2011). This could explain the cognitive deficit found in some children with ES. Moreover, in our case, the lesional deafferentation can be the substrate for an almost continuous ES, since both initiation and termination of spindle oscillations are thought to originate in thalamocortical neurons (Luppi 2005). Thus, we postulate that in some cases a partial functional cortical differentiation could generate ES.

ACKNOWLEDGMENTS

There was no corporate sponsorship of this study. None of the authors has received any form of payment for their work and there is no conflict of interest in this study.

ORCID

Paulo Afonso Medeiros Kanda http://orcid.org/0000-0002-0959-0540

REFERENCES

Akaboshi S, Koeda T, Houdou S. Transient extreme spindles in a case of subacute Mycoplasma pneumoniae encephalitis. Acta Paediatr Jpn (Overseas edition) 1998; 40:479–482.

Brandalise S, Odone V, Pereira W, Andrea M, Zanichelli M, Aranega V. Treatment results of three consecutive Brazilian cooperative childhood ALL protocols: GBTLI-80, GBTLI-82 and -85. ALL Brazilian Group. Leukemia 1993; 7 Suppl 2:S142–145.

Cyriac S, Rajendranath R, Sagar TG. Early CNS toxicity after intrathecal methotrexate. Indian J Hematol Blood Transfus 2008; 24:186–187.

Ebersole JS, Pedley TA. Current Practice of Clinical Electroencephalography. Philadelphia: Lippincott Williams & Wilkins; 2003.

Gibbs E, Gibbs F. Extreme spindles: correlation of electroencephalographic sleep pattern with mental retardation. Science 1962; 138:1106–1107.

Heatwole CR, Berg MJ, Henry JC, Hallman JL. Extreme spindles: a distinctive EEG pattern in Mycoplasma pneumoniae encephalitis. Neurology 2005; 64:1096–1097.

Luppi P-H. Sleep: Circuits and Functions. Boca Raton, FL: CRC Press; 2005.

Niedermeyer E, Capute AJ. A fast and spikey spindle variant in children with organic brain disease. Electroencephalogr Clin Neurophysiol 1967;23:67–73.

Niedermeyer E, Schomer DL, da Silva FHL. Niedermeyer's Electroencephalography: Basic Principles, Clinical Applications, and Related Fields. Philadelphia: Wolters Kluwer Health/Lippincott Williams & Wilkins; 2011.

Peyrache A, Battaglia FP, Destexhe A. Inhibition recruitment in prefrontal cortex during sleep spindles and gating of hippocampal inputs. Proc Natl Acad Sci USA 2011; 108:17207–17212.

Reddick WE, Glass JO, Helton KJ, Langston JW, Xiong X, Wu S, Pui CH. Prevalence of leukoencephalopathy in children treated for acute lymphoblastic leukemia with high-dose methotrexate. Am J Neuroradiol 2005; 26:1263–1269.

Shibagaki M, Kiyono S, Watanabe K. Nocturnal sleep in severely mentally retarded children: abnormal EEG patterns in sleep cycle. Electroencephalogr Clin Neurophysiol 1980; 49:337–344.

Spinosa MJ, Garzon E. Sleep spindles: validated concepts and breakthroughs. J Epilepsy Clin Neurophysiol 2007; 13:179–182.

Steriade M, Deschenes M, Domich L, Mulle C. Abolition of spindle oscillations in thalamic neurons disconnected from nucleus reticularis thalami. J Neurophysiol 1985; 54:1473–1497.

Westmoreland BF, Klass DW. Unusual EEG patterns. J Clin Neurophysiol 1990; 7:209–228.